

# Craniocervical Misalignment Masquerading as Facial Pain: Options for Diagnosis and Management

Louis R. Vita , Angelo Colavita , Roy W. Sweat , Matthew H. Sweat & Caroline Vitez

To cite this article: Louis R. Vita , Angelo Colavita , Roy W. Sweat , Matthew H. Sweat & Caroline Vitez (2020) Craniocervical Misalignment Masquerading as Facial Pain: Options for Diagnosis and Management, CRANIO®, 38:6, 351-354, DOI: [10.1080/08869634.2020.1823795](https://doi.org/10.1080/08869634.2020.1823795)

To link to this article: <https://doi.org/10.1080/08869634.2020.1823795>



© 2020 The Author(s). Published with license by Taylor & Francis Group, LLC.



Published online: 12 Oct 2020.



Submit your article to this journal [↗](#)



Article views: 742



View related articles [↗](#)



View Crossmark data [↗](#)

## Craniocervical Misalignment Masquerading as Facial Pain: Options for Diagnosis and Management

### Introduction

Many practitioners are involved in the diagnoses of facial pain, including dentists, chiropractors, physical therapists, and pain management physicians. It is the dental practitioner's inherent responsibility to determine whether the facial pain is from an odontogenic origin, the most common source, or if it stems from one of the many non-odontogenic sources. Non-odontogenic sources may include TMJ structural disorders, sinus-referred pain, muscle spasms, or be of a vascular, glandular, neoplastic, or trigeminal nerve origin. Many times, an often misunderstood cervicogenic source may be the cause of this facial pain. Facial pain and headache/migraines originating from a misalignment at the craniocervical junction (CCJ) can oftentimes be a common occurrence and can be mistaken as a structural/dysfunctional TMJ issue. In determining if facial pain can be a consequence of a CCJ joint dysfunction, the location of that pain must be established and considered. Any pain located posterior to the distribution of the trigeminal system, which includes the angle of the mandible and the inferior border of the mandible, may originate from a CCJ joint dysfunction. As a consequence of a misalignment of the CCJ, facial pain may also be accompanied by headaches in the back of the head, which includes the occipital region (skull base), as well as the vertex, frontal, and temporal regions with, oftentimes, associated neck pain. A CCJ joint dysfunction consists of structural changes to the relationship between the skull base and the first two vertebrae of the neck, the atlas (C1) and the axis (C2).

### Neuroanatomy of the craniocervical junction

An understanding of the underlying neuroanatomy is critical in the assessment of pain in the craniocervical junction area. The cervical spine is made up of seven vertebrae divided into upper and lower sections. The upper cervical spine is composed of the first two vertebrae, classically named the atlas and axis [1]. The term craniocervical junction is used to describe the area that includes the base of the skull (occiput), the atlas, the axis, part of the brainstem and spinal cord, the vasculature in and out of the brain, as well as the muscles and

connective tissues that act to stabilize it. It is at the CCJ that the base of the skull, the occiput (Co), is linked to the upper cervical spine, enclosing part of the brainstem and spinal cord. The nerve roots of C1 and C2 exit the spine at the CCJ. At the lateral aspect of the atlas bilaterally, there are two foramen through which the vertebral arteries pass as they ascend to supply the cerebral vasculature. The integrity of the brainstem, spinal cord, C1 and C2 nerve roots at the CCJ is directly a function of the proper alignment of the atlas in relation to the head and neck.

### Symptoms and mechanism of a craniocervical junction dysfunction

CCJ joint dysfunction that typically refers pain to the head/skull base and facial region is often due to a structural misalignment of that region. The head is supported by the atlas (C1). The atlas must be in a neutral/level position for the head to sit vertically over the spine. Due to trauma, which may include macro traumatic events, such as motor vehicle accidents (MVA) and sport related injuries, along with continuous postural strains, the atlas bone can misalign. When patients have such a misalignment, they may present in dental practices and medical offices with facial pain, headache, cervical muscular spasms, dizziness, ear ringing, ear clogging, and sleep disturbances.

TMJ disorders and C1 misalignments are separate entities with overlapping symptoms. Therefore, one must learn to identify and examine for a CCJ misalignment in patients who present with these constellations of symptoms. Often, patients are treated for a TMJ disorder, and these symptoms do not completely resolve due to the presence of CCJ joint dysfunction as a primary source of the patient's facial pain. Considering this, both systems must be examined and treated appropriately.

### Four theories that postulate how facial pain can develop from a craniocervical junction dysfunction

When the atlas misaligns, one or more of the following four conditions can develop: cervical nerve

impingement, vertebrobasilar artery insufficiency/compromise, myofascial trigger point referred pain pattern, and trigeminocervical nucleus convergence activation.

- (1) Misalignment of the first cervical segment can cause impingement of the two first cervical nerve roots (C1-C2) as they exit the spine.

There is a sensory distribution of the CCJ nerves (C1-C2) to the back of the head, which covers the area posterior to the distribution of the trigeminal system. This area includes the posterior  $\frac{3}{4}$  of the ear, the angle of the mandible, and the inferior border of the mandible.

Many practitioners and dentists hear patients complain of pain at the angle or inferior border of the mandible. If the origin of the pain is determined to be non-odontogenic and it is not originating from the TMJ, then we must consider the possibility of a cervicogenic origin, i.e., craniocervical joint dysfunction.

- (2) Any shift/misalignment of the atlas can cause a direct impingement of the vertebral artery as it passes through the transverse foramen, thus plausibly compromising blood flow to the vertebrobasilar system.

According to Blumenfeld [2], “The vertebrobasilar system gives rise to multiple branches to provide blood supply to the brainstem and cerebellum.” The pontine branches of the basilar artery supply many cranial nerves, including the trigeminal, facial, and acoustic cranial nerves. Chronic ischemia of the vertebral arteries can thus lead to disorders such as trigeminal neuralgia, tinnitus, hearing loss, tremor, Horner’s syndrome, ataxia, and loss of pain and temperature sensation [3].

- (3) Myofascial trigger points in the muscles of the neck can refer pain to the face and head. Travell and Simons [4] have stated that there can be myofascial trigger point development from structural inadequacies, postural stress, and constriction of muscles. At the CCJ, the structural inadequacy is a chronic C1 vertebra misalignment that generates mechanical stress, which then leads to the formation of trigger points.

The upper trapezius and the sternocleidomastoid (SCM) are the two muscles that most commonly develop trigger points as a result of an atlas malposition. Upper trapezius muscle trigger points can refer pain in the occipital, temporoparietal, lateral orbital, and masseter regions. Trigger points in the SCM have a referred pain pattern that can range from pain in the eye, TMJ, and the ear to the top and back of the head [4].

- (4) Facial pain can arise from CCJ joint dysfunction via the trigeminocervical nucleus convergence.

The most caudal part of the trigeminal cervical nucleus, which includes the spinal trigeminal nucleus, is also called the trigeminal nucleus caudalis. “Medium and small diameter primary sensory fibers conveying crude touch, pain, and temperature sensation enter the lateral pons with the trigeminal nerve and descend in the spinal trigeminal tract to synapse in the spinal trigeminal nucleus [2].” Compression of the cervical nerve roots through the atlanto-occipital and the atlanto-axial joints causes migraine due to the afference of cervical and trigeminal nerve fibers to the neurons of the trigeminal sensory nucleus [5]. All headaches are mediated by the trigeminocervical nucleus and are initiated by noxious stimulation of the endings of the nerves that synapse on this nucleus, by irritation of the nerves themselves, or by disinhibition of the nucleus [6]. Compression of the C1 and C2 nerves by an atlas misalignment can also cause facial pain through the nociceptive afferents from the trigeminal nerves. There is interdependence between the cervical and the trigeminal sensory-motor systems. Disease or trauma in one system may induce pain and dysfunction in the other system [7].

### **Treatment options for a craniocervical misalignment**

The most common treatments sought by patients to alleviate neck pain are traditional chiropractic, physiotherapy and massage therapy treatments, oral medications, and pain management to possibly include injections. Treatment of the CCJ is a separate treatment modality that includes different procedures. Some of these methods are manipulative, while others are non-manipulative. The Atlas Orthogonal procedure is considered a non-manipulative, low force treatment used to correct misalignments of the craniocervical junction. The Atlas Orthogonal therapy corrects these anatomical misalignments with low force as well as great precision, which allows better efficiency in reducing facial pain.

### **Atlas orthogonal therapy**

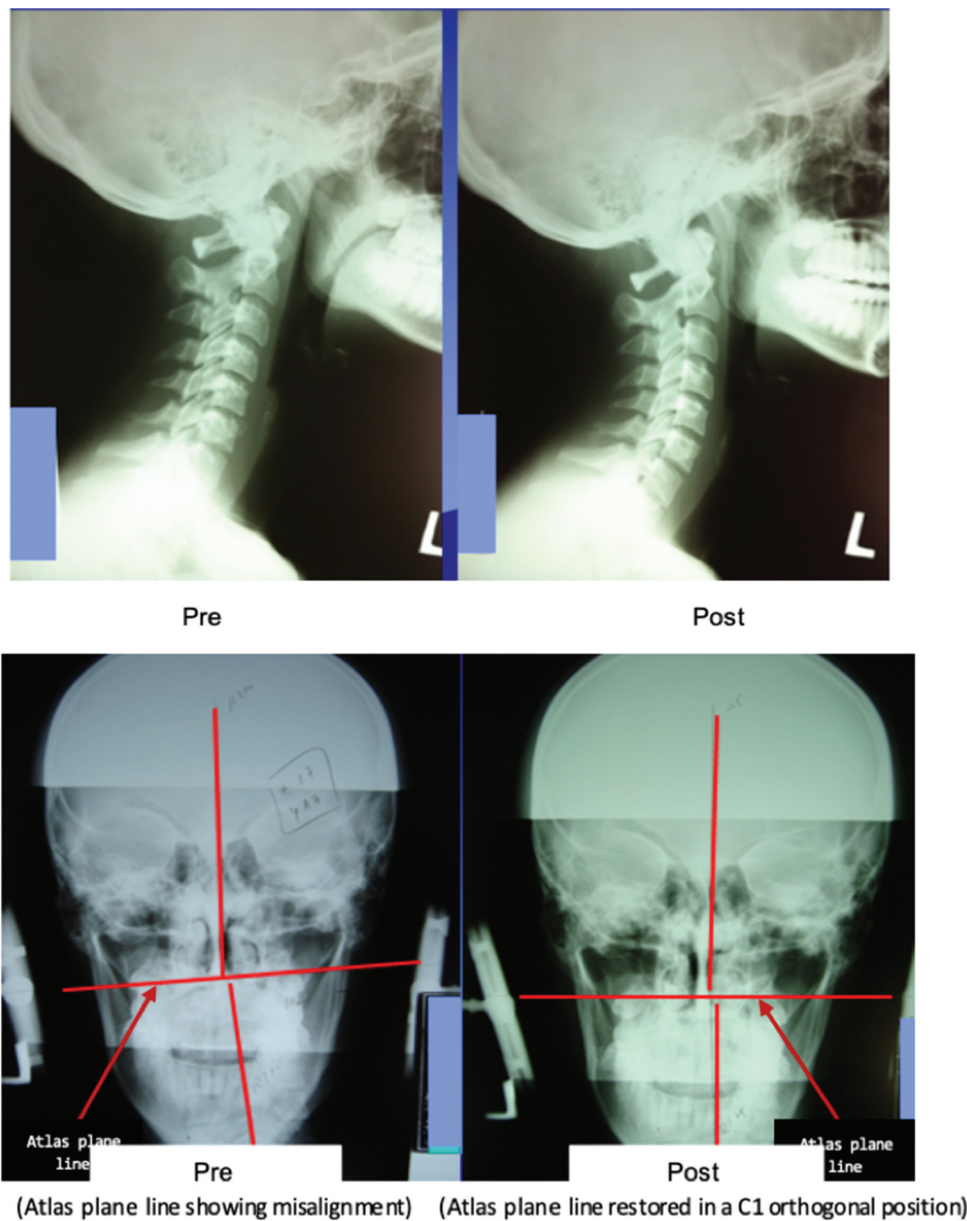
Atlas misalignments are corrected with the “Atlas Orthogonal Percussion Instrument.” This instrument utilizes a gentle mechanical force, designed to restore the misalignments found at the CCJ. In order to determine if the patient is a candidate for this procedure, the first step to the Atlas Orthogonal therapy is to take very

precise weight bearing postural cervical x-rays that will guide the treatment. A 3-plane series of x-rays are acquired, including sagittal, coronal, and axial to determine the degree of misalignment. Following treatment, post-cervical x-rays are taken to confirm that the misalignments of the craniocervical junction have been corrected and restored to the best anatomical position (Figure 1).

Treatment using the Atlas Orthogonal Percussion Instrument consists of an aluminum stylus that imparts a mechanical tap in the form of a vibration. This vibration moves the two-ounce atlas bone into place as the patient remains in a neutral position. The aluminum stylus of the

instrument is placed between the mastoid bone and ramus of the jaw under the patient's ear, which interfaces with the skin. This mechanical tap is what restores the C1 segment back into the corrected position.

This procedure is painless, accurate, and does not involve any manual cervical rotation or manipulation. The patient's response to the Atlas Orthogonal procedure varies in terms of outcome. It would be expected that the length of time the condition has existed could correlate to time needed to heal the inflamed/injured structures. Structural correction outcomes can range from immediate elimination of neck muscle spasm to the reduction or elimination of occipital headaches, ear symptoms, facial



**Figure 1.** Pre and post C1 treatment correction.

pain, and increase in cervical range of motion. Following the initial correction of misalignments at the craniocervical junction, a healing phase is necessary to ensure that the proper position of the atlas is maintained. Once corrected, the patients do need to have follow-up check-ups and occasionally, in chronic complex cases, might need further re-correction of the atlas misalignment. Patients are often required to adjust their postural habits, e.g., sleeping positions and work-related postures, and eliminate compensatory postural habits that can contribute to mechanical strains that might cause misalignments of the craniocervical junction.

## Discussion

Misalignment of the upper cervical spine, specifically at the craniocervical junction, is an overlooked source of headache and facial pain of non-odontogenic origin. The postulated sources affected by C1 misalignment are nerve pressure, vertebral artery compromise, myofascial trigger points, or activation of the trigeminal cervical nucleus convergence.

The Atlas Orthogonal procedure, using a precision low-force percussion instrument, corrects the mechanical disrelation at the craniocervical junction. This non-manipulative therapy thereby reduces impingement upon the postulated sources of headache and facial pain.

A palpatory examination of the upper cervical spine may be considered by practitioners who treat headache and facial pain as an aid in determining the origin. When the atlas is evaluated as a possible cause, the Atlas Orthogonal procedure can be recognized as a viable, non-invasive treatment option.

## References

- [1] Rosa S, Baird JW, Harshfield D, et al. Craniocervical junction syndrome: anatomy of the craniocervical and atlantoaxial junctions and the effect of misalignment on cerebrospinal fluid flow. *Hydrocephalus – Water Brain*. Bora Gürer, IntechOpen. 2018. DOI:10.5772/intechopen.72890.
- [2] Blumenfeld H. *Neuroanatomy through clinical cases*. Sunderland (MA): Sinauer Associates Inc.; 2002.
- [3] University of Nebraska Medical Center [Internet]. Vertebral basilar insufficiency. Omaha, Nebraska. [cited 2012 Jul 5]. Available from: <http://nebraskamed.com/neurosurgery/vertebral-basilar-insufficiency>
- [4] Travell J, Simons D. *Myofascial pain and dysfunction: the trigger point manual*. Baltimore (MD): Williams & Wilkins; 1983.
- [5] Jansen J, Markakis E, Rama B, et al. Hemicranial attacks or permanent hemicrania—a sequel of upper cervical root compression. *Cephalalgia*. 1989;9(2):123–130.
- [6] Bogduk N. Anatomy and physiology of headache. *Biomed Pharmacother*. 1995;49(10):435–445.
- [7] Browne PA, Clark GT, Kuboki T, et al. Concurrent cervical and craniofacial pain: a review of empiric and basic science evidence. *Oral Surg Oral Med Oral Pathol Oral Radiol Endod*. 1998;86(6):633–640.

Louis R. Vita DDS, FAGD  
*Hackensack University Medical Center,*  
*Hackensack, NJ, USA*  
 Angelo Colavita DC, BCAO  
*Private Practice, Clifton, NJ, USA*  
 Roy W. Sweat DC, BCAO  
*Private Practice, Atlanta, GA, USA*  
 Matthew H. Sweat DC, BCAO  
*Private Practice, Atlanta, GA, USA*  
 Caroline Vitez DC, BCAO, DACNB  
*Private Practice, Moorestown, NJ, USA*